

Evidence for superior parietal impairment in Williams syndrome

Abstract—Parietal lobe impairment is hypothesized to contribute to the dramatic visual-spatial deficits in Williams syndrome (WS). The authors examined the superior and inferior parietal lobule in 17 patients with WS and 17 control female adults (CNLs). The right and left superior parietal lobule gray matter volumes were significantly smaller in patients with WS than in CNLs, even after controlling for total cerebral gray matter. Impaired superior parietal function could explain WS visual-spatial and visual-motor problems.

NEUROLOGY 2005;64:152–153

M.A. Eckert, PhD; D. Hu, BS; S. Eliez, MD; U. Bellugi, PhD; A. Galaburda, MD; J. Korenberg, MD; D. Mills, PhD; and A.L. Reiss, MD

Williams syndrome (WS) typically results from a 17 to 19 gene deletion on chromosome 7 (7q11.23) that produces a unique cognitive profile of relative strengths and weaknesses.¹ Poor visual-spatial processing is the most profound cognitive deficit and is the foundation of a dorsal stream deficit hypothesis for WS.² This hypothesis suggests that anomalous development of dorsal stream visual pathways leads to impaired visual-spatial processing.

The dorsal stream includes a dorsodorsal stream that projects from V1 to V6 and into the superior parietal lobule and a ventrodorsal stream that projects from V1 to MT and into the inferior parietal lobule.³ Neuroanatomic support for the dorsal stream hypothesis in WS includes small parietal lobe volume and increased parietal lobe gyrification,⁴ but questions remain about the specificity of these findings to the superior or inferior parietal lobules. We collected volumetric measures of the superior and inferior parietal lobules to determine whether the dorsodorsal stream (superior parietal lobule) or ventrodorsal stream (inferior parietal lobule) is more affected in WS.

Materials and methods. Seventeen women with WS were recruited and evaluated as part of a program project designed to examine associations between WS behavior, neurophysiology, neuroanatomy, and molecular genetics. Participants were excluded from the study if they exhibited confounding medical or neurologic histories, such as epilepsy. A WS diagnosis was made based on fluorescent in situ hybridization results for a deletion of the elastin gene. All subjects with WS in this study had typical deletions.¹

Seventeen healthy control women (CNLs) were recruited to serve as a comparison group. The CNL participants were selected

to be age matched to the WS participants (mean age: WS, 28.9 years; CNL, 27.1 years). CNL participants had no history of major psychiatric, neurologic, or cognitive impairment. Two CNL participants were recruited from the Stanford University local community. The remaining CNL and WS participants were recruited nationally and from the University of California, San Diego local community. The institutional review boards of both universities approved the procedures, and participants provided informed written consent for the study.

MRI protocol. Brain scans for each subject were acquired using a GE-Signa 1.5-T scanner (General Electric, Milwaukee, WI) at the University of California San Diego Medical Center Magnetic Resonance Imaging Institute, Scripps Clinic in San Diego, or Stanford University. Sagittal brain images were acquired at each site with the same three-dimensional volumetric radiofrequency spoiled gradient echo pulse sequence using the following scan parameters: repetition time, 24 ms; echo time, 5 ms; flip angle, 45°; number of excitations, 2; matrix size, 256 × 192; field of view, 24 cm; slice thickness, 1.2 mm; 124 contiguous slices.

Neuroanatomic measures. BrainImage v5.x was used to remove nonbrain tissues from the images, correct equipment-related image artifacts, segment cerebral tissue components (gray, white, and CSF), normalize image position, parcellate the cerebral cortex into four lobes, and measure the superior and inferior parietal lobule.⁵ The entire parietal lobe was manually traced in coronal plane of section. Parietal lobe boundaries were defined as tissue posterior to the postcentral sulcus, anterior to a plane extending laterally from the parietal-occipital sulcus, and superior to the cingulate sulcus. The parietal lobe regions of interest were measured on gray scale images, subdivided using the intraparietal sulcus to delineate the superior from inferior parietal lobules in consecutive axial planes of section, and overlaid on gray and white segmented images to obtain gray and white matter volumes. Raters were blind to group membership, and intraclass correlation demonstrated inter-rater reliability was >0.90 for each anatomic variable.

Results. The table presents the mean and SD for each anatomic variable by WS and CNL group. Multivariate analysis of covariance (MANCOVA) was used to 1) compare group differences in the left and right hemisphere superior and inferior parietal lobule gray matter measures, while controlling for total cerebral gray; and 2) compare group differences in the left and right hemisphere superior and inferior parietal lobule white matter measures, while controlling for total cerebral white matter volume.

Gray matter. The MANCOVA results showed a main effect of group (Wilks F, 2.14; $p < 0.05$) and total cerebral gray matter (Wilks F, 11.6; $p < 0.001$), indicating significant group differences in parietal lobule volume over and above differences attributed to total cerebral gray matter. In particular, the figure shows that CNLs demonstrated greater right superior ($F[1,34] = 4.35$; $p < 0.05$) and left superior parietal gray matter volumes ($F[1,34] = 6.42$; $p < 0.05$) than patients with WS after controlling for total cere-

From the Department of Psychiatry and Behavioral Sciences (Drs. Eckert and Reiss, D. Hu), Stanford University School of Medicine, Palo Alto, CA; Division of Child and Adolescent Psychiatry (Dr. Eliez), Geneva University School of Medicine, Switzerland; Salk Institute Laboratory for Cognitive Neuroscience (Dr. Bellugi), La Jolla, CA; Department of Neurology (Dr. Galaburda), Harvard Medical School, Boston, MA; Department of Pediatrics (Dr. Korenberg), University of California, Los Angeles, CA; and Department of Psychology (Dr. Mills), Emory University, Atlanta, GA.

Supported by NICHD grant 5P01HD033113–080003.

Received April 15, 2004. Accepted in final form August 16, 2004.

Address correspondence and reprint requests to Dr. Mark Eckert, 401 Quarry Road, Room 1358, Department of Psychiatry, Stanford University, Stanford, CA 94305; e-mail: meckert@stanford.edu

Table Group mean and standard SD for each anatomical variable

	CNL		WS	
	Mean	SD	Mean	SD
Right superior				
Parietal GM	20.0	3.0	16.9	3.3
Left superior				
Parietal GM	21.1	3.6	17.3	2.9
Right inferior				
Parietal GM	22.8	3.6	22.6	3.6
Left inferior				
Parietal GM	22.1	5.0	22.2	4.6
Right superior				
Parietal WM	15.1	3.6	10.3	1.8
Left superior				
Parietal WM	13.3	2.9	9.7	1.9
Right inferior				
Parietal WM	16.1	5.0	13.5	3.9
Left inferior				
Parietal WM	16.4	3.7	13.6	3.1
Cerebral GM	564.4	57.1	530.4	37.9
Cerebral WM	449.9	61.2	363.6	43.5

CNL = control group; WS = Williams syndrome; GM = gray matter; WM = white matter.

bral gray matter. There were no significant group differences for the right and left inferior parietal lobule measures after controlling for total cerebral gray matter.

White matter. The MANCOVA results showed that group differences in each of the parietal lobule white matter volumes could be attributed to total cerebral white matter (Wilks F, 27.0; $p < 0.001$) and that group was not significant after controlling for total cerebral white matter (Wilks F, 2.10; NS).

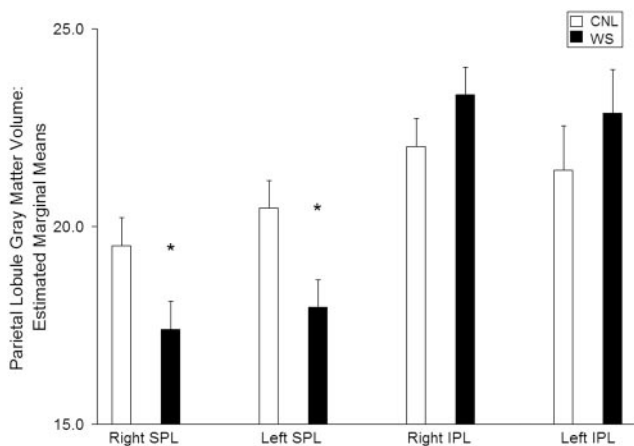


Figure. Williams syndrome (WS) and control (CNL) group comparisons for the superior and inferior parietal lobule gray matter estimated marginal means after controlling for total cerebral gray matter. SPL = superior parietal lobule; IPL = inferior parietal lobule; * $p < 0.05$. Error bars represent SE.

Discussion. The results of this study suggest that right and left dorsodorsal visual streams (superior parietal lobule) are particularly affected in women with WS. The right and left superior parietal lobules are critical for visually guided motor tasks and disengaging attention from locations in visual space.^{6,7} Atypical development of the superior parietal lobule, as well as other dorsodorsal stream structures, may explain why visual-motor impairment and “sticky fixation” are hallmarks of WS.⁸

The parietal lobule gray matter findings are consistent with a voxel-based morphometry study showing less gray matter in the right and left superior parietal lobule.⁴ However, these findings are probably not indicative of a primary deficit in the superior parietal lobule. The WS occipital lobe exhibits the greatest lobar decrease in volume,⁴ abnormal neuronal packing density, and small neuronal size.⁹ These visual cortex anomalies may have downstream effects on the superior parietal lobule architecture and function.

The group differences in each of the parietal lobule white matter volumes could be attributed to total cerebral white matter rather than specific reductions within the superior or inferior parietal lobules. These findings appear to reflect system-wide effects of the WS deletion on brain development and connectivity between occipital-parietal and frontal regions engaged in visual-spatial processing. WS cerebral volume differences are reported to be most prominent in visual system areas.⁴

Limitations of this study and directions for future research include potential influences of sex, hypertension, and strabismus on the WS superior parietal lobule volume and other dorsodorsal stream structures. We predict future studies will show dorsodorsal stream pathway anomalies in WS, demonstrate anomalous cytoarchitecture,⁹ and exhibit anomalous activation in functional imaging studies.¹⁰

Acknowledgment

The authors thank the participants and their families.

References

- Korenberg JR, Chen XN, Hirota H, et al. VI. Genome structure and cognitive map of Williams syndrome. *J Cogn Neurosci* 2000;12(suppl 1):89–107.
- Atkinson J, King J, Braddick O, et al. A specific deficit of dorsal stream function in Williams' syndrome. *Neuroreport* 1997;8:1919–1922.
- Rizzolatti G, Matelli M. Two different streams form the dorsal visual system: anatomy and functions. *Exp Brain Res* 2003;153:146–157.
- Reiss A, Eckert MA, Rose FE, et al. An experiment of nature: brain anatomy parallels cognition and behavior in Williams syndrome. *J Neurosci* 2004;24:5009–5015.
- BrainImage 5.x [program] Stanford: Stanford Psychiatry Neuroimaging Laboratory, 2003.
- Galletti C, Kutz DF, Gamberini M, et al. Role of the medial parieto-occipital cortex in the control of reaching and grasping movements. *Exp Brain Res* 2003;153:158–170.
- Posner MI, Walker JA, Friedrich FJ, et al. Effects of parietal injury on covert orienting of attention. *J Neurosci* 1984;4:1863–1874.
- Atkinson J, Anker S, Braddick O, et al. Visual and visuospatial development in young children with Williams syndrome. *Dev Med Child Neurol* 2001;43:330–337.
- Galaburda AM, Holinger DP, Bellugi U, et al. Williams syndrome: neuronal size and neuronal-packing density in primary visual cortex. *Arch Neurol* 2002;59:1461–1467.
- Mobbs D, Garrett AS, Menon V, et al. Anomalous brain activation during face and gaze processing in Williams syndrome. *Neurology* 2004;62:2070–2076.